



ISSN (E): 2277- 7695

ISSN (P): 2349-8242

NAAS Rating: 5.03

TPI 2019; 8(4): 927-928

© 2019 TPI

www.thepharmajournal.com

Received: 13-02-2019

Accepted: 16-03-2019

T Sunitha

M.V. Sc. Scholar, Department of Livestock Production Management, College of Veterinary and Animal Sciences, Kerala Veterinary and Animal Sciences University, Mannuthy, Thrissur, Kerala, India

MR Roshin

M.V.Sc. Scholar, Department of Microbiology, College of Veterinary and Animal Sciences, Kerala Veterinary and Animal Sciences University, Mannuthy, Thrissur, Kerala, India

RT Venkatachalapathy

Professor, Department of Animal Genetics and Breeding, College of Veterinary and Animal Sciences, Kerala Veterinary and Animal Sciences University, Mannuthy, Thrissur, Kerala, India

Correspondence

T Sunitha

M.V. Sc. Scholar, Department of Livestock Production Management, College of Veterinary and Animal Sciences, Kerala Veterinary and Animal Sciences University, Mannuthy, Thrissur, Kerala, India

Treatment of contagious ecthyma (ORF) lesions in Malabari goats using ethno veterinary medicine

T Sunitha, MR Roshin and RT Venkatachalapathy

Abstract

An observation on the incidence of contagious ecthyma (ORF) in 15 kids was made at University Goat and Sheep Farm, Mannuthy functioning under Kerala Veterinary and Animal Sciences University. The animals developed pyrexia with restricted milk and kid starter intake, appeared dull, depressed with lesions on nostrils and lips and inside the mouth. Later, the entire ear of the affected kids was seen covered with the thick scabby lesions. The morbidity was 100 percentage, but there was no mortality. The animals were isolated and lesions were wiped with cotton dipped in potassium permanganate solution. An ethno veterinary medicine which comprised of neem leaves, turmeric and few drops of lemon juice and a pinch of salt was applied over the lesions twice daily. There was complete recovery within two weeks.

Keywords: Contagious ecthyma, Malabari goats, ethno-veterinary medicine

Introduction

ORF, also known as sore mouth, contagious pustular dermatitis, infectious labial dermatitis or scabby mouth (Thomas *et al.*, 2003) [7] is caused by parapox virus (Buchen Osmond, 2003) [1] producing scabby lesions around the mouth and nostrils (Chan *et al.*, 2017) with more severity in goats than in sheep (Nandi *et al.*, 2011) [6]. The mouth and feet are most commonly affected. Lesions start to appear as a small reddened area which later starts to wipe a clear fluid. This fluid then dried and adhered to the skin forming thick scabs, which when forcefully removed, led to profuse bleeding. There is no effective treatment as it is self-limiting viral disease, but the use of topical antibacterial agents can promote early recovery (Wilson *et al.*, 2002) [10].

Materials and Methods

A total of 15 kids at pre-weaning stage were affected with ORF in University goat and Sheep Farm, Mannuthy, under Kerala Veterinary and Animal Sciences University during November and December 2018. The affected animals were dull and depressed and had pyrexia during the initial stages. The skin lesions first appeared on the commissures of lips and then extended to all areas around the mouth and even to the gums (reddish papular lesions) leading to difficulty in suckling milk (Fig. 2). The nostrils and ears were also severely affected and covered with thick scabs (Fig. 1). These scabs persisted for weeks even though antibiotics and vitamin supplements were administered to counteract secondary bacterial infection. Later, treatment was initiated with external application of herbal paste prepared by grinding a few neem leaves and turmeric in 1:2 ratio. A half lemon was squeezed into the mix along with a pinch of salt and was made into a paste. The lesion was wiped with cotton dipped in potassium permanganate solution. Fresh paste was prepared every time and applied twice daily.

Results and Discussion

The lesions healed and a major portion of the scabs fell off by 10th day of application (Fig.3) and completely healed uneventfully within two weeks (Fig 4).The milk and feed intake resumed to the normal. No mortality was reported during the period. Thus by shifting to ethno-veterinary medicine, one can minimize the monetary loss owing to treatment courses using antibiotics, antiseptics, anti-inflammatory drugs and antihistamines (Maphosa and Masika, 2010, Tyasi and Nkohla 2015 and Tyasi *et al.*, 2015) [4, 8, 9]. Side effects and antibiotic resistance due to over use of these drugs can also be avoided to an extent. Marginal farmers can rather resort to readily available, accessible and affordable alternatives of this kind

(Laffont *et al.*, 2001; McGaw *et al.*, 2007) [3, 5]. However, safety and efficacy of this treatment has to be further subjected to detailed study, so that they could form an alternative cost effective strategy for ORF.



Fig 1: kid exhibiting ORF lesions on ears

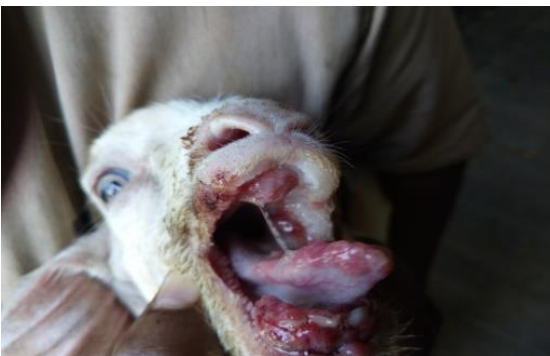


Fig 2: kid exhibiting ORF lesions inside mouth

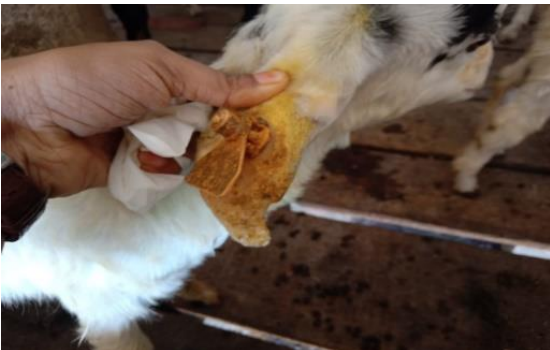

Fig 3: Lesions on 10th day of application

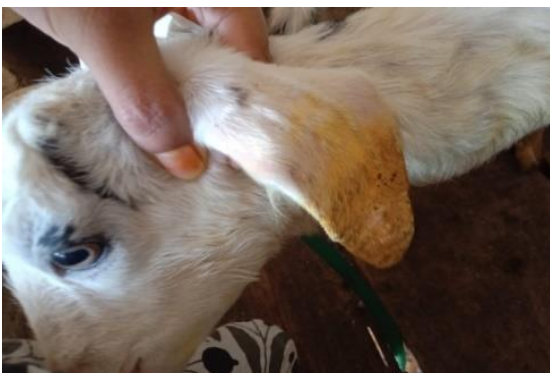

Fig 4: Completely healed at 14 days

ORF in Malabari kids. After further validation of the result, this treatment protocol could be used cost effectively in goats against ORF.

Acknowledgement

The authors are highly thankful to the casual labourer engaged in University Goat and Sheep Farm, Mannuthy, who evinced keen interest in preparing the paste to treating the animals.

References

1. Buchen Osmond C. Taxonomy and classification of viruses. In: Manual of Clinical Microbiology. 8th ed., ASM Press, Washington DC. 2003; 2:1217-1226.
2. Chan KW, Lin JW, Lee SH, Liao CJ, Tsa MC, Hsu WL, *et al.* Identification and phylogenetic analysis of orf virus from goats in Taiwan. *Virus Genes.* 2007; 35:705-712.
3. Laffont CM, Alvernia M, Bousquet MA, Toutain PL. Licking behavior and environmental contamination arising from pour on ivermectin for cattle. *J Inter. Parasitol.* 2001; 31:1687-1692.
4. Maphosa V, Masika PJ. Ethnoveterinary uses of medicinal plants: a survey of plants used in the Ethnoveterinary control of gastrointestinal parasites of goats in the Eastern Cape Province, South Africa. *Pharmac. Bio.* 2010; 48:697-702.
5. McGaw LJ, Van der MD, Eloff JN. *In vitro* anthelmintic, antibacterial and cytotoxic effects of extracts from plants used in South African ethno-veterinary medicine. *Vet. J.* 2007; 173:366-372.
6. Nandi S, Ujjwal KDe, Chowdhury S. Current status of contagious ecthyma or orf disease in goat and sheep - A global perspective. *Small. Rumin. Res.* 2011; 96:73-82.
7. Thomas K, Tompkins DM, Sainsbury AW, Wood AR, Dalziel R, Nettleton PF *et al.* A novel poxvirus lethal to red squirrels (*Sciurus vulgaris*). *J Gen. Virol.* 2003; 84, 3337-3341.
8. Tyasi TL, Nkohla MB. In-vivo validation of the *Elephantorrhiza elephantina*'s efficacy as alternative in the control of coccidia infections in goats. *African J Agric. Sci. Tech.* 2015; 3(4):225-229.
9. Tyasi TL, Chao LZ, Gxasheka M, Nkohla MB. Effectiveness of *elephantorrhiza elephantina* as traditional plant used as the alternative for controlling coccidian infections in goats. *J Bio. Agric. Healthcare.* 2015; 5(8):163-167.
10. Wilson DJ, Scott PR, Sargison ND, Bell G, Rhind SM. Effective treatment of severe facial dermatitis in lambs. *Vet. Rec.* 2002; 150:45-46.

Conclusion

Ethno-Veterinary medicine prepared out of neem leaves, turmeric and lemon juice was found very effective in treating