



ISSN (E): 2277- 7695

ISSN (P): 2349-8242

NAAS Rating: 5.03

TPI 2019; 8(9): 364-367

© 2019 TPI

www.thepharmajournal.com

Received: 06-07-2019

Accepted: 10-08-2019

Sridevi P

Department of Veterinary
Anatomy and Histology, Rajiv
Gandhi Institute of Veterinary
Education and Research,
Kurumbapet, Tamil Nadu, India

Rajalakshmi K

Department of Veterinary
Anatomy and Histology, Rajiv
Gandhi Institute of Veterinary
Education and Research,
Kurumbapet, Tamil Nadu, India

SivaKumar M

Department of Veterinary
Anatomy and Histology, Rajiv
Gandhi Institute of Veterinary
Education and Research,
Kurumbapet, Tamil Nadu, India

Gross anatomical studies on the splanchno-cranium of Emu (*Dromaius novaehollandiae*)

Sridevi P, Rajalakshmi K and SivaKumar M

Abstract

The splanchnocranium consisted of single mandible, vomer and hyoid bones and paired quadrate, lacrimal, nasal, premaxilla, maxilla, Zygomatic (jugal), palatine and pterygoid bones. The ethmoid consisted of horizontal and perpendicular bony plates; the latter formed the interorbital septum caudally and joined the nasal septum rostrally. The lacrimal bone was larger and fused with the frontal and nasal bone; it had a frontal process in its caudal portion and a thin, pointed lacrimal process below. The nasal bone formed the dorsal and lateral boundaries of the nasal cavity, sutured rostrally with the frontal process of premaxilla and formed the upper beak. The Turbinates consisted of three cartilaginous nasal conchae. Premaxilla was V shaped and formed the major part of the upper beak. The maxilla was a V shaped small delicate bone which formed the caudal rim of the upper beak and part of bony palate. Zygomatic bone was thin rod like. The palatine bones were roughly triangular in shape. The pterygoid bone was a thin delicate bony plate situated on either sides of the Vomer. Vomer was an unpaired long tubular bone situated in the median plane. Quadrate bone consisted of a body and three processes otic, mandibular and orbital and was located between the neurocranium and maxillo-palatine apparatus. The mandible was U shaped with two slightly curved rami which fused rostrally and formed the Mandibular symphysis and enclosed a wide inter-mandibular space. Hyoid bone consisted of a rod shape unpaired body the basihyoid which at its rostral end had an articular surface for the single flat entoglossum.

Keywords: Splanchnocranium, turbinates, mandible bones, emu

Introduction

The size of the Splanchno-cranium depended on the mandibular apparatus, development and shape and size of the beak which in turn was related to the feeding habits of birds. A light toothless beak was highly modified for its varied feeding behaviours. Splanchno-cranium formed a movable articulation with the neuro-cranium and a portion of its constituent bones formed movable joints with one another. The jaw joint articulation between the quadrate and articular process of the mandible was an important vestige of the bird's ancestral relation to the reptiles. In addition the large incomplete bony orbit assisted in the bird's sensory mechanism. The movement of the upper beak was brought about by naso-frontal joint. The upper beak undergoes a rotation rostro-dorsally or caudo-ventrally and relative to this movement passively stabilizes the position of the mandible when the jaw is closed. In addition it enhances the jaw opening strength and reduces the effects of shock and furnishes attachment to jaw muscles. At the junction of the cranium with the nasal and premaxilla, the upper jaw is raised and also the bone is flexible and thin and the interorbital septum is absent. All these features facilitate to increase the size of the gape. The present study was conducted to explore in detail about the gross morphology of the various components of the splanchno-cranium in the skull of emu.

Materials and Methods

The present study was conducted on three adult emu birds, brought for post mortem to the department of veterinary pathology at Rajiv Gandhi Institute of Veterinary Education and Research, Puducherry. Skull was removed after natural maceration and the gross morphological features of the splanchnocranium was studied.

Results and Discussion

The splanchnocranium consisted of single mandible, vomer and hyoid bones and paired quadrate, lacrimal, nasal, premaxilla, maxilla, Zygomatic (jugal), palatine and pterygoid bones. Due to the large sized orbital cavities, there was a nasal disposition of ethmoid which was not a part of the neurocranium.

Correspondence

Sridevi P

Department of Veterinary
Anatomy and Histology, Rajiv
Gandhi Institute of Veterinary
Education and Research,
Kurumbapet, Tamil Nadu, India

The ethmoid consisted of horizontal and perpendicular bony plates, the horizontal part was present below the frontal and nasal bone. The perpendicular plate presented a large comma shaped opening at the junction with orbital wings of pre sphenoid. It formed the interorbital septum (Fig 1) caudally and rostrally joined nasal septum, the olfactory foramina was observed behind the ethmoidal foramina. The ethmoid was not a component of neurocranium similar observations were noticed in ostrich by Moselhy *et al.*, 2018 ^[9], Kumar and Singh 2014 ^[6] in emu and Nickel *et al.*, 1977 ^[10] in domestic birds.

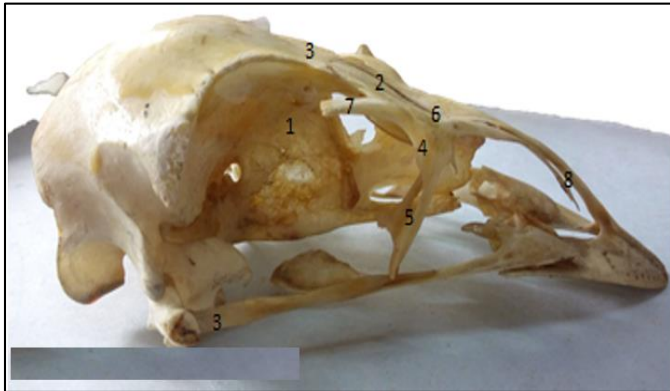


Fig 1: Lateral view of Emu skull 1. Frontal 2. Frontal process of frontal 3. Nasal process of frontal 4. Lacrimal 5. Lacrimal process of lacrimal 6. Nasal 7. Lateral nasal process of nasal 8. Premaxillary process of nasal ritual

The lacrimal bone (Fig 1) was larger and fused with the frontal and nasal bones. It had a frontal process in its caudal portion and a thin, pointed lacrimal process below, which was curved, bifid, directed downward and backward and formed the cranio-ventral margin of the orbit. This concurs with the findings of Kumar and Singh 2014 ^[6] in emu. The lacrimal process (Fig 1) also formed a part the ventral margin of the bony orbit. Nickel *et al.*, 1977 ^[10] reported that lacrimal bone was small in fowl and pigeon while it was large in duck and goose and bore the flat caudally directed lacrimal process. In the duck, lacrimal process was so close to the temporal process of squamous temporal and formed almost a complete lower orbital ring, the latter was absent in fowl and pigeon. A similar feature was observed in the present study in emu.

The nasal bone (Fig 1) formed the dorsal and lateral boundaries of the nasal cavity, sutured rostrally with the frontal process of premaxilla and formed the upper beak (Fig 2). Similar finding were reported by Nickel *et al.*, 1977 ^[10] in domestic birds and Kumar and Singh 2014 ^[6] in emu. It presented three processes namely frontal, premaxillary and lateral nasal process, while Kumar and Singh 2014 ^[6] in emu and by Nickel *et al.*, 1977 ^[10] in domestic birds, had observed process frontales, intermaxillares and maxillares. Frontal process was lodged posteriorly between the lacrimal bones laterally and frontal process of frontal bone medially. The premaxillary process of nasal bone extended rostrally ventral to the frontal process of premaxilla. The lateral nasal process was curved caudo laterally, extended posteriorly and formed one third of the ventral margin of bony orbit and also contributed partly in the formation of lateral boundary of nasal cavity, whereas in ostrich Moselhy *et al.*, 2018 ^[9]

reported that the dorsolateral boundary of nasal cavity was limited by the lateral process of nasal bone. Dorsal boundary of the nasal cavity was formed by frontal, nasal, lacrimal and premaxilla. The ventral boundary was formed by maxilla and palatine process of premaxilla, palatine bone and cranial part of pterygoid bone. The osseous nasal septum separated the two halves of nasal cavity. The nasal septum was formed rostrally by vomer and caudally by vertical plate of ethmoid which fused with the interorbital septum. The Turbinates consisted of three cartilaginous nasal conchae anterior, middle and posterior, of which the middle concha was the largest.

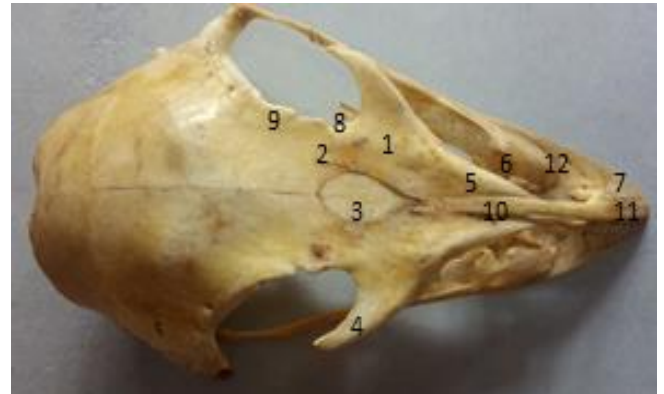

Fig 2: Dorsal view of Emu skull 1. Nasal 2. Frontal process of nasal 3. Frontal process of frontal 4. Lateral nasal process of nasal 5. Premaxillary process of nasal 6. Maxilla 7. Premaxilla 8. Lacrimal 9. Frontal process of lacrimal 10. Frontal process of premaxilla 11. Culmen 12. Premaxillary process of maxilla

Premaxilla was “V” shaped (Fig 2) whereas it was ‘U’ shaped in ostrich as observed by Martina and soley 2017 ^[7]. The bone was paired and was observed to form the major part of the upper beak. It varied greatly in shape and size in agreement with Nickel *et al.*, 1977 ^[10] in domestic birds. It was composed of a rostral body and 3 paired process, frontal, maxillary and palatine. Similar observation was reported by Nickel *et al.*, 1977 ^[10] in domestic birds and Kumar and Singh (2014) ^[6] in emu. The frontal processes were united with each other and extended upto the frontal process of frontal bone. Rostrally it merged with its body along the middorsal line and formed a bony ridge the culmen, Martina and Soley (2017) ^[7] in ostrich. This extended from the base of the frontal process of premaxilla to the tip of the upper beak.

Numerous bony pits were observed on dorsal and ventral aspects of body of the premaxilla. Maxillary process was thick and wide rostrally and became narrow, tapered behind and joined the maxilla. The palatine process of both sides merged with each other cranially and caudally and enclosed a cleft. Similar findings was reported in emu by Kumar and Singh (2014) ^[6].

The maxilla was small, V shaped and a delicate bone (Fig 2) forming the caudal rim of the upper beak and part of bony palate and it was fused with premaxilla, palatine, zygomatic and nasal bones. Similar findings were reported by Kumar and Singh (2014) ^[6] in emu and Nickel *et al.*, 1977 ^[10] in domestic birds. It consisted of a body and two processes namely premaxillary and pterygoid process. Body was fused with palatine process of premaxilla.

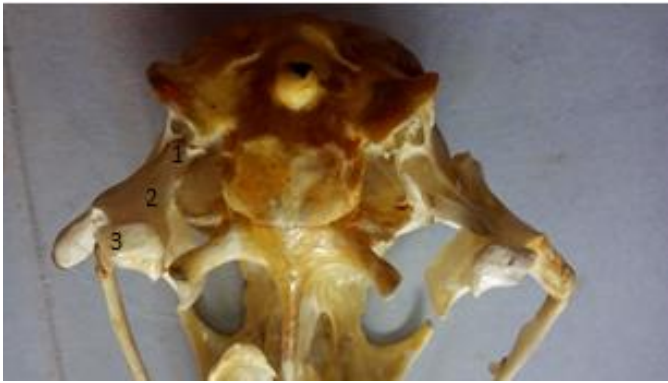


Fig 3: Ventral view of posterior aspect of emu skull 1. Otic process of Quadrate 2. Orbital process of quadrate 3. Mandibular process of quadrate

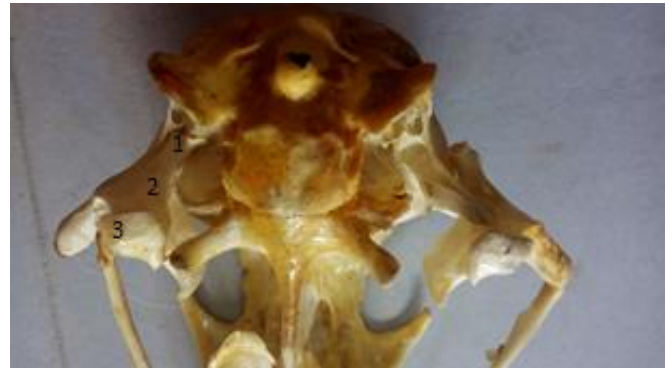


Fig 5: Ventral view of posterior aspect of emu skull 1. Otic process of quadrate 2. Orbital process of quadrate 3. Mandibular process of quadrate

Zygomatic bone (Fig 3) was a thin rod like paired bone which prolonged from maxilla behind and extended to the quadrate bone. It had a jugal process which was fused anteriorly with the maxilla, behind which it is was called jugal bone and its posterior end articulated with the quadrate forming the quadrate-jugal (Fig 3). These findings concur with the reports by Kumar and Singh (2014) [6] in emu and Nickel *et al.*, 1977 [10] in domestic birds.

Quadrate bone consisted of a body and three processes otic, mandibular and orbital (Fig 4). Similar observations were reported by Moselhy *et al.*, 2018 [9] in ostrich. On the other hand, Nickel *et al.*, 1977 [10] in domestic birds and by Kumar and Singh (2014) [6] in emu reported the presence of otic, orbital and articular process. Quadrate bone was located between the neurocranium and maxillo-palatine apparatus and formed an important role in kinetics which concurs with the findings in emu by Kumar and Singh (2014) [6] and Nickel *et al.*, 1977 [10] in domestic birds. The mandibular process was the largest process and ventral and was divided by a groove into two condyles, lateral and medial. The latter was the largest and placed at a more lower level and it articulated with pterygoid anteriorly. The lateral condyle articulated with quadratojugal. Ataligian *et al.*, 2014 [1] had observed condyles which articulated with the mandible in grey heron. The otic process was deeply placed between zygomatic process laterally, occipital behind and basisphenoid medially. It articulated with the concave articular groove of external acoustic meatus. The orbital process had a wide distal end which projected rostro-medially into the orbit.

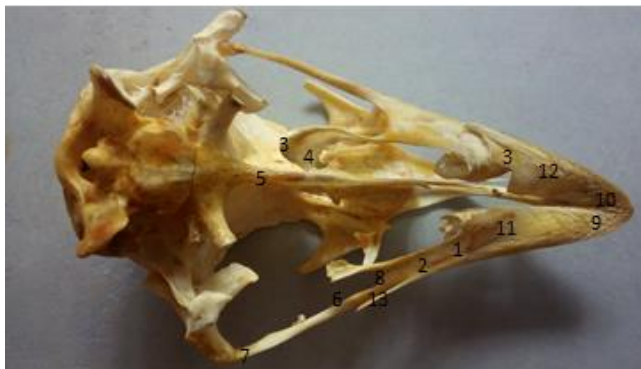

Fig 4: Ventral view of Emu skull 1. Palatine 2. Palatine process of premaxilla 3. Pterygoid 4. Pterygoid process of maxilla 5. Vomer 6. Jugal 7. Quadratojugal 8. Jugal process 9. Body of premaxilla 10. Premaxilla 11. Maxilla 12. Body of maxilla 13. Maxillary process of premaxilla

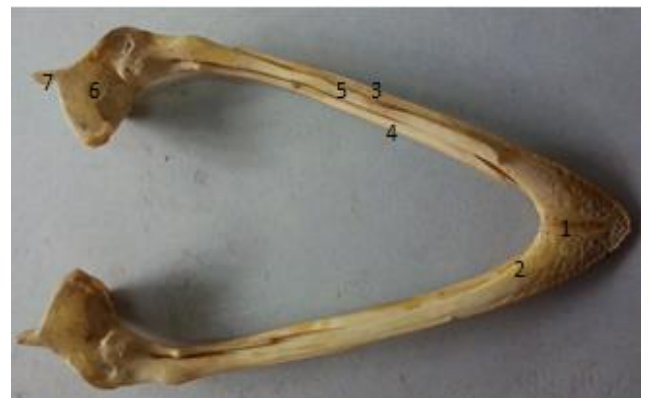

Fig 6: Dorsal view of mandible 1. Mandibular symphysis 2. Dental 3. Dorsal process of dental 4. Ventral process of dental 5. Supra angular 6. Articular 7. Angular

The palatine bones were roughly triangular in shape (Fig 3) while Moselhy *et al.*, 2018 [9] reported that they were quadrilateral in ostrich. According to Nickel *et al.*, 1977 [10] in duck and goose they were in the form of bony plates. It roofed the pharynx and the palatine bones of either side were separated from each other by a wide cleft which is as reported by Nickel *et al.*, 1977 [10] in domestic birds. It articulated anteriorly with maxilla, laterally with maxillary process of premaxilla and posteriorly with pterygoid bone.

The pterygoid bone was a thin delicate bony plate situated on either side of the vomer and had a curved pterygoid process which joined the palatine and maxilla anteriorly (Fig 3).

Vomer (Fig 3) was an unpaired long tubular bone situated in the median plane, which fused behind with presphenoid and joined the nasal septum anteriorly. Similar findings were reported by Moselhy *et al.*, 2018 [9] in ostrich. Nickel *et al.*, 1977 [10] reported that vomer was rudimentary in fowl and pigeon.

The mandible was 'V' shaped (Fig 5) in the present study similar to that reported in ostrich by Moselhy *et al.*, 2018 [9]. It had two slightly curved rami which fused rostrally and formed the mandibular symphysis. The rami enclosed a wide intermandibular space which conformed to the shape of the upper beak. These findings are in accordance to the reports of Moselhy *et al.*, 2018 [9] in ostrich and Nickel *et al.*, 1977 [10] in domestic birds. It consisted of four fused bony components dental, supra angular, articular and angular. The dorsal and

ventral surfaces showed numerous foramina. Similar observations were reported in ostrich and emu by Martina and Soley 2017 [7]. But Nickel *et al.*, 1977 [10] in fowl recorded six parts; articular, angular, supra angular, complementary, opercular and dental, while Proctor and Lynch (1993) [11] in rock pigeon and Feduccia (1975) [3] in fowl observed five parts of mandible namely splenial, angular, supra angular, articular and prearticular. The dental bone of either side were fused with each other to form a wide flat bony plate and conformed to the shape of the upper beak. A similar finding was reported by Kumar and Singh (2014) [6] in emu and Moselhy *et al.*, 2018 [9] in ostrich. The dental bone was divided into two processes dorsal and ventral between which was intercalated the supra angular bone which fused caudally with the articular component, while rostrally it had two processes, dorsal and ventral intercalated with similar process of dental bone. Just behind the process, the medial surface had the mandibular foramen which opened into the mandibular canal. In emu the articular part was prismatic and showed three facets. Two were oval of which the medial facet was larger, medial and placed at a higher level and lateral was smaller and both these facets were separated by a ridge. The caudal facet was placed behind the lateral facet. This is in agreement with findings of Kumar and Singh (2014) [6] in emu and Hassan 2012 [4] in cattle egret. But Moselhy *et al.*, 2018 [9] reported the presence of only two facets of which medial was larger in ostrich. The angular part in emu presented a medial process which was directed forward and outward and a lateral process directed inward. This concurs with findings of Moselhy *et al.*, 2018 [9] in ostrich and Hassan (2012) [4] in hooded crow.

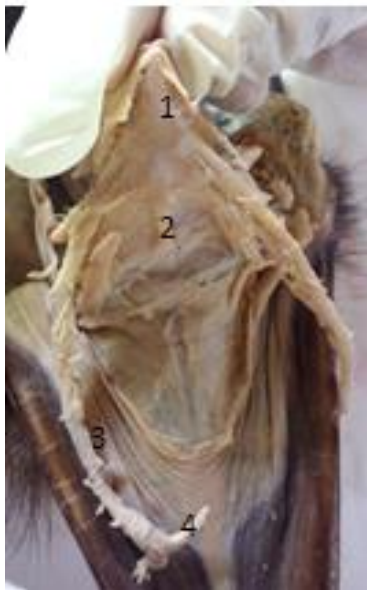

Fig 7: Dorsal view of hyoid bone 1. Basihyoid bone 2. Urohyal bone 3. Bony part of hyoid ramus 4. Cartilaginous part of hyoid ramus

Hyoid bone consisted of a rod shape unpaired body the basihyoid which at its rostral end had an articular surface for the single flat entoglossum (Fig 6) Nickel *et al.*, 1997 [10] reported that the entoglossum was double in the fowl and shovel-like in the duck and goose. The body caudally had another articular surface for the urohyoid. The basihyoid carried an articular surface on either side for the rami. The rami of the hyoid were located laterally against the neurocranium. The urohyoid was observed as a flattened prominent bony plate. In contrast, Kumar and Singh (2014) [6]

had reported that urohyoid in emu was not prominent. The rami of hyoid bone consisted of a rostral bony rod like part which was continued caudally by a cartilaginous part, in concurrence with the observations of Moselhy *et al.*, 2018 [9] in ostrich.

Acknowledgement

Authors are thankful to the Dean, Rajiv Gandhi Institute of Veterinary Education and Research, Puducherry for providing the basic infrastructure for carrying out this research work.

References

1. Atalgin H, Buyukcopur B, Kurul I. A detailed evaluation of the skeletal elements of the skull in the grey heron (*Ardea cinerea*). Turk J Vet Anim Sci. 2014; 38:370-376.
2. Dyce KM, Sack WO, Wensing CJG. Textbook of Veterinary Anatomy. 3rd Ed. Saunders, Philadelphia, London, New York, St. Louis, Sydney, Toronto, 2002, 789-791.
3. Feduccia A. Aves Osteology. In Sisson and Grossman's. The Anatomy of the Domestic Animals, 5th Ed. R., W.B. Saunders Company, Philadelphia, London & Toronto, 1975; 2:1790-1794.
4. Hassan SA. Comparative Morphological Studies on the Quadrato-mandibular Articulation in Hooded Crow (*Corvus cornix*) and Cattle Egret (*Bubulcus ibis*). J Vet. Anat. 2012; 5(1):43-46.
5. King A.S. and McLelland J. Birds, their Structure and Function. Bailliere Tindall, London, 1984.
6. Kumar P, Singh G. Gross Anatomy of Axial Skeleton in Emu (*Dromaius novaehollandiae*). Indian Journal of Veterinary Anatomy. 2014; 26(2):87-91.
7. Martina Crole R, John Soley T. Bony pits in the ostrich (*Struthio camelus*) and Emu (*Dromaius novaehollandiae*) Bill tip the anatomical record. 2015; 300:1705-1715.
8. McLelland JA. Color of atlas of avian anatomy Wolfe Publishing Ltd, 1990.
9. Moselhy AA, Sherif KH, Mohamed A, Hanaa M. El-Ghazali. Anatomical features of bones and bony cavities of the ostrich skull (*Struthio camelus*). Int J Anat Res. 2018; 6:5390-5398. Doi: 10.16965/Ijar.2018.213.
10. Nickel R, Schummer A, Seiferle E. Anatomy of the Domestic Birds, chapter (Skeleton of the head), Verlag Paul Parey, Berlin and Hamburg, 1977, 20-25.
11. Proctor N, Lynch P. Manual of ornithology: Avian structure and function. New Haven: Yale University Press, 1993.