



ISSN (E): 2277-7695  
ISSN (P): 2349-8242  
NAAS Rating: 5.23  
TPI 2022; SP-11(9): 1206-1209  
© 2022 TPI  
[www.thepharmajournal.com](http://www.thepharmajournal.com)  
Received: 16-07-2022  
Accepted: 20-08-2022

**Nadia Mildred Dsouza**  
Rajiv Gandhi Institute of  
Veterinary Education and  
Research, Pondicherry, India

**Aneesh Viegas**  
Research Scholar,  
Veterinary Medicine,  
Goa, India

**N Gurunathan**  
Rajiv Gandhi Institute of  
Veterinary Education and  
Research, Pondicherry, India

**N Arul Jothi**  
Rajiv Gandhi Institute of  
Veterinary Education and  
Research, Pondicherry, India

**Corresponding Author:**  
**Nadia Mildred Dsouza**  
Rajiv Gandhi Institute of  
Veterinary Education and  
Research, Pondicherry, India

## Surgical management of diaphragmatic hernia in a cat: A case report

**Nadia Mildred Dsouza, Aneesh Viegas, N Gurunathan and N Arul Jothi**

### Abstract

A 3-year-old female domestic short hair cat weighing 3.2 kg was presented to the hospital with dyspnoea and lethargy. On radiographic examination, cranial displacement of stomach axis, difficulty in visualizing the liver, and loss of diaphragmatic line was observed. Surgical herniorrhaphy was carried out via a ventral midline coeliotomy approach to the diaphragm by using propofol 8 mg/kg IV and isoflurane anesthesia without any complication. The diaphragm was repaired with simple interrupted sutures using PDS (size 2-0). After repairing the hernia, thoracocentesis were carried out with a three-way cannula placed through the diaphragm and the air within the thorax was aspirated with an injector to achieve negative pressure. Analgesia was provided with 0.1 mg/kg, IV, meloxicam postoperatively for 3 days. On 10<sup>th</sup> day post-surgery, almost all the clinical signs and radiographs including diaphragmatic line and liver appeared normal. The animal made an uneventful recovery.

**Keywords:** Cat, diaphragmatic hernia, herniorrhaphy, thoracocentesis

### Introduction

Diaphragmatic hernia occurs when the diaphragm is damaged, allowing abdominal organs to move into the thoracic cavity. Traumatic diaphragmatic hernias are prevalent in dogs and cats, but the congenital form is uncommon [3].

Trauma, particularly motor vehicle accidents, causes the majority of diaphragmatic hernias in dogs and cats. When a severe blow to the abdominal wall generates an abrupt increase in intraabdominal pressure, the lungs rapidly collapse (assuming the glottis is open), resulting in a substantial pleuroperitoneal pressure gradient. The pressure differential between the thorax and the abdomen, on the other hand, may rip the diaphragm. The tears occur in the diaphragm's weakest areas, which are usually the muscular sections [6]. The weaker muscular portions of the diaphragm rupture causing tear in the direction of the muscle fibers, or tear along the attachments to the ribs. These are classified as radial and circumferential tears, respectively [2].

The death rate linked with diaphragmatic hernia varies, although it was 17.6% in a recent feline study [4]. The liver, small intestine, stomach, omentum, and spleen are the most commonly herniated organs into the chest [4]. Patients may show only minor indications of respiratory failure, or they may be completely asymptomatic [7].

A radiographic examination is required for a definitive diagnosis. Thoracocentesis must be performed prior to radiography if there is a pleural effusion. The presence of barium sulphate (positive contrast) in the small intestine or/and stomach visualized in thoracic cavity, loss of diaphragmatic line and cardiac silhouette, dorsal or lateral displacement of lung surfaces, gas in the thoracic cavity, and presence of gas in the thoracic cavity are all symptoms of this diagnosis [5]. The patient can have a definitive surgical repair (herniorrhaphy) as soon as he or she shows signs of cardiovascular stability; dominantly, it was recommended that the patient wait at least 24 hours after presenting [8].

When a herniated stomach distends (with or without volvulus) and causes respiratory distress that cannot be treated with thoracocentesis and/or oxygen assistance, emergency surgery may be required [9]. Adhesions between abdominal contents and thoracic tissues are to be expected in patients with delayed diaphragmatic hernia.

### Case history

A 3-year-old domestic short hair breed, intact cat weighing 3.2kg was presented at Viegas pet clinic in Goa with a history of fall from a height. The owners reported that, post the fall, the cat had developed a respiratory distress with significant abdominal breathing.

On presentation the next day, the cat was quiet, alert and responsive with mild dyspnoea, tachypnea and abdominal breathing. On physical examination, the patient presented regular nutritional status and hydration, pale mucosa, 102°F of core temperature and normal lymph nodes. Cardiac auscultation revealed a muffled heart sound with a normal heart rate and rhythm. The respiratory movements of the left chest were found to be decreased compared to the right side. Normal abdominal organs could not be appreciated during palpation. Oxygenation status was assessed by pulse oximetry which was 88%. Decompensation was suspected due to inadequate oxygenation and poor peripheral perfusion; therefore, emergency stabilization was initiated. Routine laboratory tests such as complete blood cell count, serum biochemistry Respiratory distress associated with thoracic trauma was suspected and a thoracic radiograph was performed.

Haematological examination showed, the total leukocyte count, MCHC and platelet count were  $3.9 \times 10^3 / \mu\text{L}$  (reference range  $5.5\text{-}19.5 \times 10^3 / \mu\text{L}$ ), 38.4% (reference range 22-38%), 102 (reference range  $200\text{-}300 \times 10^3 / \mu\text{L}$ ) respectively. Serum biochemical tests demonstrated that the levels of the enzyme's aspartate aminotransferase 284 mg/dl (reference range 10-50 mg/dl), exceeded the upper reference. All other parameters were within normal range. Diagnosis of diaphragmatic hernia was made by the clinical findings and the use of radiography and it was confirmed by surgical exploration. Patients was stabilized for shock and respiratory dysfunction as much as possible before radiography. Two-view thoracic radiographs were obtained under mild sedation with Butorphanol [0.2 mg/kg IV]. Radiographic examination revealed that loss of diaphragmatic shadow and heart silhouette, decreased abdominal detail, a cranially shifted stomach axis, and difficulty in visualizing the liver. Considering these radiographic findings, a presumptive diagnosis of diaphragmatic hernia was made. Surgery was opted to resolve the hernia.

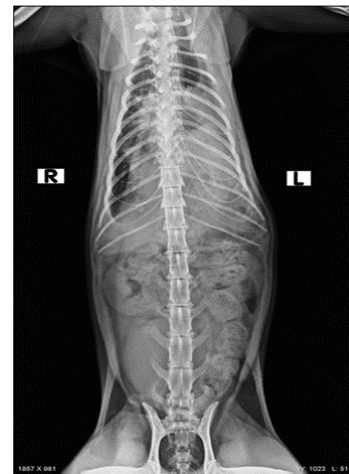
### Pre-anaesthetic preparation and anaesthesia

The cat was premedicated with midazolam (Midazolam (0.2 mg/kg IV) (Dormicum, Roche) and buprenorphine (0.005-0.02 mg/kg IV) (Bupregesic). Preoxygenation of the patient for 3 to 5 minutes prior to induction was done followed by rapid induction and intubation. Anaesthesia was induced with propofol (Neorof) in dose of 6 mg/kg IV, and maintained with 1-3% isoflurane (IsoFlo) in oxygen under controlled by intubation with endotracheal tube (size 3.5) ventilation, and a constant rate infusion of Ketamine (low dose) @ 0.5-1 mg/kg IV was provided. Amoxicillin and clavulanic acid (Augmentin, Glaxo Smith Kline) was used before and after surgery, @ 20 mg/kg i/v. The patient was positioned in dorsal recumbency. Respiratory, electro-cardiogram, SpO<sub>2</sub> and temperature were monitored during surgery. During the surgery Ringers lactate solution at the rate 2 ml/kg/hour was administered intravenously.

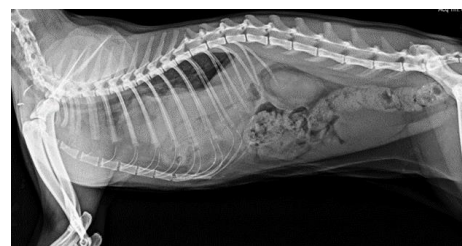
### Surgical procedure

Exploratory coeliotomy through a ventral midline approach extending from xiphoid cartilage to the umbilicus, revealed a large defect of the ventral portion of the diaphragm. Patient was stable because of ventilator set at 32 tidal volumes (10 ml/kg body weight) but at time of initiating coeliotomy, SpO<sub>2</sub> stats dropped to 57 (fig.no. 8), as a result ambubag was used to deliver oxygen manually. The stomach and liver were

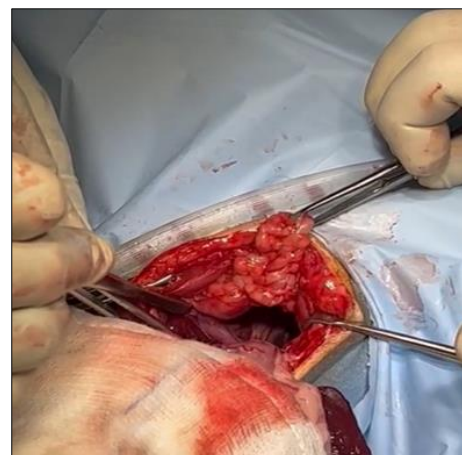
retracted from the thoracic cavity. The herniated portion of the liver showed congestion and mild adhesions. The diaphragm was repaired with simple continuous suture pattern using 2/0 PDS and a rib (plication technique) was incorporated in the continuous suture for added strength. Lungs were hyperinflated and air was removed from the pleural cavity before the application of last suture. With the use of a 3-way stop cock and 50 cc syringe, extra pleural air was evacuated from the thorax until a gentle negative pressure was obtained. On exploring the entire abdominal cavity for association injuries, no abnormalities were detected. The muscle and subcutaneous tissues were opposed using PDS 2/0 and 3/0 by simple continuous suture pattern, respectively, followed by skin using monocryl size 3/0, intradermal suture pattern.



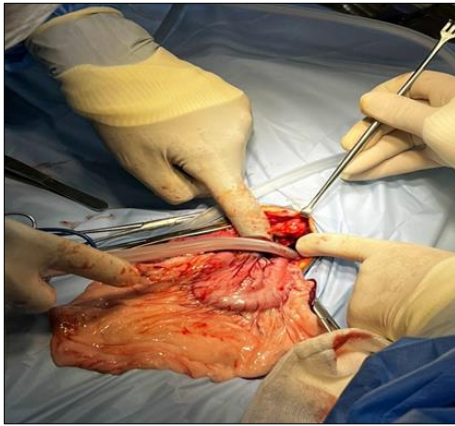
**Fig 1:** Radiographic view Pre-operative (ventro dorsal and left lateral positioning)



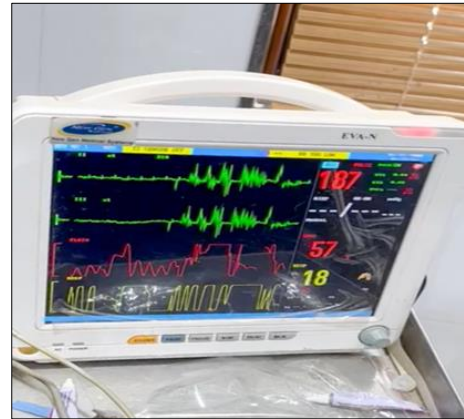**Fig 2:** Radiographic view Pre-operative (ventro dorsal and left lateral positioning)



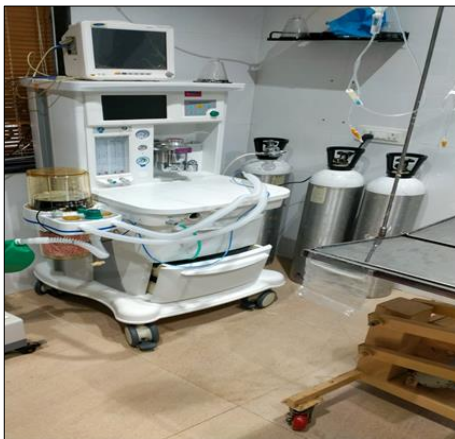**Fig 3:** Diaphragmatic tear on the ventral



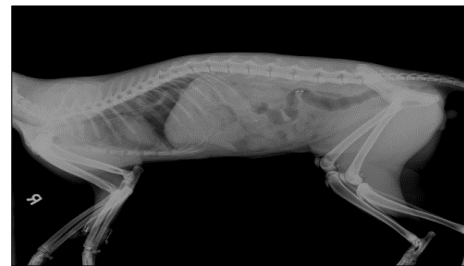**Fig 4:** Thoracocentesis aspect of the diaphragm



**Fig 8:** Patient monitor showing sudden decrease in SpO<sub>2</sub> on



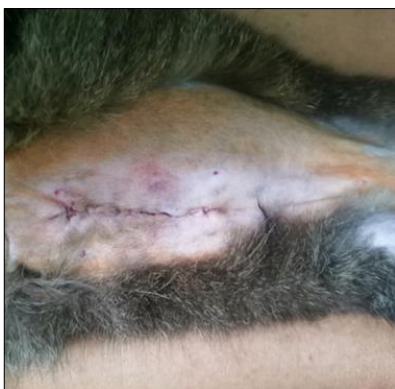**Fig 5:** Anaesthesia workstation with. In built ventilator



**Fig 9:** Post-operative radiograph



**Fig 6:** Post-operative oxygen stabilization



**Fig 7:** Post-operative suture site

**Post-operative care**

The patient was monitored carefully for the next six to eight hours after surgery intensively for development of complications, and adequate oxygen support and pain management was provided. Based on the perioperative surgical evaluation and the postoperative clinical response, the prognosis was assessed to be good. Post-operative antibiotics (Amoxicillin and clavulanic acid @20mg/kg q12hours P.O/IV) and analgesics (Meloxicam 0.1mg/kg q24hours P.O) were administered for 5 day and 3 days respectively. Post-operative complications were not noticed and the animal had an uneventful recovery. A follow-up radiographic examination 10 days following surgery revealed a normal diaphragm outline and the lack of anomalies associated with the organs in the abdomen thorax.

**Discussion**

The clinical manifestations of diaphragmatic hernia are variable and depend on the extent and form of the herniation. The digestive tract (vomiting, diarrhoea, anorexia, weight loss) and the respiratory system are the most common clinical symptoms (dyspnoea, cough, and wheeze). However, in the present case, dyspnoea, lethargy and muddled heart sounds were evident. Routine radiography, as well as contrast radiography and ultrasonography, can often be used to diagnose a diaphragmatic hernia<sup>2</sup>. Fluid therapy is a crucial step in improving tissue perfusion and oxygen delivery in cats with diaphragmatic hernia, which is characterised by bradycardia, hypotension, and hypovolemia<sup>[14]</sup>. Ringers lactate solution was given intravenously at a rate of 2ml/kg/hour during the procedure. When larger portions of the liver are herniated, there may be a serum increase of enzymes activity, such as ALT and AST<sup>[10]</sup>, which was observed in the present case. Hepatic tissue injury was also responsible for the increase in serum albumin and total protein contents. Depending on the location of the diaphragmatic rupture certain organs herniate more

frequently, with the liver being the most common <sup>[17]</sup>. With the liver and stomach displaced in this case, a left-sided diaphragmatic hernia was observed.

The interval between induction and herniorrhaphy should be kept as short as possible, and oxygen should be administered both before and after the surgery <sup>[16]</sup>. The period of anaesthesia prior to surgical intervention was kept as brief as possible in the present case. Before and after the operation, oxygen assistance was administered. Dogs and cats with respiratory insufficiency should be maintained with inhalation anaesthetics (i.e., isoflurane or sevoflurane) since it has advantages of rapid and more precise control of anaesthetic depth than intravenous anaesthetics <sup>[16]</sup>. Every diaphragmatic herniorrhaphy procedure should include diaphragmatic repair as well as an extensive abdominal examination to rule out any blunt force trauma sequelae such as ruptured urinary bladder or hemoabdomen. No abnormalities were noticed in the present case<sup>17</sup>. When the defect is greater, however, abdominal organs can move more freely into the pericardial sac, resulting in pericardial adhesions and organ entrapment or strangling, leading to gastrointestinal, respiratory, and/or cardiac alterations <sup>[7]</sup>. Concerning the surgical approach, the defect was closed using simple continuous suture with 3-0 polydioxanone by incorporating the 10<sup>th</sup> rib. Autogenous grafts like fascia Lata or flaps the thoracoabdominal and latissimus dorsi alone or in combination with the serratus anterior muscle in pediatric surgery <sup>[12]</sup> or of the oblique and transversus abdominis muscles in dogs can also be use but are are rather complex techniques with prolonged operating times, which could be detrimental in critically ill patients<sup>13</sup>. Prognosis following herniorrhaphy in the present case of diaphragmatic hernia in cat was good.

### Conclusion

In the present case, it was determined that adequate anaesthetic protocols and critical care practices may have improved the surgery's success.

### Acknowledge

The authors are thankful to the Dean, Rajiv Gandhi Institute of Veterinary Education and Research, Pondicherry for the facilities provided to conduct the study.

### Reference

1. Diaphragmatic Hernia 20 <https://www.acvs.org/small-animal/diaphragmatic-hernia>.
2. Worth AJ, Machon RG. Traumatic diaphragmatic herniation: Pathophysiology and management. *Compend Contin Educ Pract Vet*. 2005;27:178-190.
3. Eric Monnet, DVM, PhD, FAHA, DACVS, DECVS. Managing diaphragmatic hernias (Proceedings). <https://www.dvm360.com/view/managing-diaphragmatic-hernias-proceedings-2011>
4. Schmiedt CW, Tobias KM, Stevenson M. Traumatic diaphragmatic hernia in cats: 34 cases (1991–2001). *J Am Vet Med Assoc*. 2003;222:1237-1240.
5. Ozer K, Guzel O Devecioglu, Aksoy YO. Diaphragmatic hernia in cats: 44 cases. *Medycyna Weterynaryjna*. 2007;63(12):1564-1567. ref.10
6. Theresa W, Fossum DVM. PhD, DACVS. Diaphragmatic Hernias: Diagnosis and Emergency Treatment. World Small Animal Veterinary Association World Congress Proceedings; c2006. <https://www.vin.com> > defaultadv1Diaphragmatic

- Hernias: Diagnosis and Emergency Treatment - VIN
7. Burns CG, Bergh MS, Mc Loughlin MA. Surgical and nonsurgical treatment of peritoneopericardial diaphragmatic hernia in dogs and cats: 58 cases (1999-2008). *J. Am. Vet. Med. Assoc*. 2013;242:643-650.
8. Legallet C, Thieman Mankin K, Selmic LE. Prognostic indicators for perioperative survival after diaphragmatic herniorrhaphy in cats and dogs: 96 cases (2001-2013). *BMC Vet Res*. 2017;13(1):16.
9. Formaggini L, Schmidt K, De Lorenzi D. Gastric dilatation-volvulus associated with diaphragmatic hernia in three cats: clinical presentation, surgical treatment and presumptive etiology. *J Feline Med. Surg*. 2008;10(2):198-201.
10. Statz GD, Moore KE, Murtaugh RJ. Surgical repair of a peritoneopericardial diaphragmatic hernia in a pregnant dog. *J Vet Emerg Crit Care*. 2007;17(1):77-85.
11. Hoddinott, Katie. Traumatic diaphragmatic hernia in a 5-month-old boxer dog. *The Canadian veterinary journal La revue vétérinaire canadienne*. 2013;54:507-9.
12. Samarakkody U, Klaassen M, Nye B. Reconstruction of congenital agenesis of hemidiaphragm by combined reverse latissimus dorsi and serratus anterior muscle flaps. *J Pediatr Surg*. 2001 Nov;36(11):1637-40.
13. Liptak JM, Brebner NS. Hemidiaphragmatic reconstruction with a transversus abdominis. Muscle flap after resection of a solitary diaphragmatic mesothelioma in a dog. *J Am Vet Med Assoc*. 2006;228(8):1204-8.
14. Nelson D. Patient care report for the stabilisation of a cat with a traumatic diaphragmatic rupture. *The Veterinary Nurse*. 2015;6(8): 498-503.
15. Besalti, Omer, Pekcan, Zeynep Calışkan, Murat & Aykut, ZG. A retrospective study on traumatic diaphragmatic hernias in cats. *Ankara Universitesi Veteriner Fakultesi Dergisi*. 2011;58:175-179.
16. Fossum Theresa Welch. Surgery of the lower respiratory system: Lungs and thoracic wall. In Theresa Welch Fossum Ed. *Small Animal Surgery*; St. Louis, MO, Mosby, 1997. p. 649-674.
17. Hoddinott K. Traumatic diaphragmatic hernia in a 5-month-old boxer dog. *Can Vet J*. 2013 May;54(5):507-9. PMID: 24155438; PMCID: PMC3624926.