



ISSN (E): 2277-7695
ISSN (P): 2349-8242
NAAS Rating: 5.23
TPI 2023; 12(5): 3714-3716
© 2023 TPI

www.thepharmajournal.com

Received: 08-03-2023

Accepted: 13-04-2023

Mohd Akil

Livestock Farm Complex, Apollo
College of Veterinary Medicine
(RAJUVAS) Jaipur, Rajasthan,
India

Pratipal Kaurav

Livestock Farm Complex, Apollo
College of Veterinary Medicine
(RAJUVAS) Jaipur, Rajasthan,
India

Rizwan Khan

Department of Veterinary Public
Health and Epidemiology,
Apollo College of Veterinary
Medicine (RAJUVAS) Jaipur,
Rajasthan, India

NS Meena

Technical Sales Officer,
Venkateshwara Hatcheries,
Ajmer Rajasthan, India

Corresponding Author:

Mohd Akil

Livestock Farm Complex, Apollo
College of Veterinary Medicine
(RAJUVAS) Jaipur, Rajasthan,
India

From diagnosis to recovery: A practical approach to ringworm treatment in cattle

Mohd Akil, Pratipal Kaurav, Rizwan Khan and NS Meena

DOI: <https://doi.org/10.22271/tpi.2023.v12.i5ar.20374>

Abstract

Ringworm is a fungal infection that can affect humans and animals, causing hair loss and scaly skin. Cows are particularly prone to this infection, with symptoms often appearing on their head, neck, and other parts of the body. A recent study was conducted at LFC, Apollo College of Veterinary Medicine in Jaipur, and on various farms found that 20 cattle calves between three months to one year old had skin lesions and tested positive for *Trichophyton* sp. Treatment with a 2% liq. Povidone iodine application, followed by a topical application of Whitefield ointment twice a day for 15 consecutive days, resulted in full recovery for all affected cows.

Keywords: Ringworm infection, Jaipur, povidone iodine, Whitefield's ointment

1. Introduction

Ringworm is a fungal infection that affects the skin and hair of animals and humans. It is caused by a group of fungi called dermatophyte, which are attracted to keratinized structures. The fungi belong to the *Trichophyton*, *Microsporum*, and *Epidermophyton* genera. However, *Trichophyton* (*T.*) *verrucosum* is an infectious agent of cattle dermatophytosis (Gudding and Lund 1995) [5]. Zoonotic pathogens like dermatophytes are responsible for causing significant public health problems and economic losses worldwide. These losses include reductions in milk and meat production, as well as damage to skin structures. It is crucial to address these issues promptly and effectively to mitigate their impact on both human and animal populations (Dalis *et al.* 2018) [3]. Dermatophytes are known to invade keratinized tissues, particularly hair fibers and the stratum corneum. This invasion results in the hydrolysis of the fiber structure, leading to hair breakage and ultimately, alopecia. The animal host's body responds with a hypersensitivity reaction to the pathogen's metabolic products, which leads to the development of lesions. However, the host's inflammatory response can be harmful to the fungus, causing the dermatophyte to move away from the affected area towards normal skin. This movement ultimately results in the development of circular lesions with alopecia, with healing occurring at the center and inflammation at the edge (Radostits *et al.* 2007; Markey *et al.* 2013) [8, 6]. It is important to note that dermatophyte can cause significant damage to the host's skin and hair. Therefore, it is crucial to seek prompt medical attention if any symptoms of dermatophyte infection are observed. Early diagnosis and treatment can prevent further damage and promote faster healing.

2. Materials & Methods

2.1 Case History and Clinical Signs

A clinical examination was conducted on a total of 20 cattle calves, ranging in age from three months to one year. These calves were located at LFC, Apollo College of Veterinary Medicine in Jaipur, as well as various villages near Jaipur. The purpose of this examination was to assess the overall health of the animals. During the examination, the skin of each animal was thoroughly inspected, and a general health assessment was conducted. This included recording body temperature, pulse rate, respiratory rate, appetite, and morbidity rates. Additionally, any skin lesions were carefully documented, including their shape, size, position, distribution, and time of appearance. During our observation of the animals, we noted the presence of characteristic lesions. These lesions were circular in shape, circumscribed, alopecic, with a heavy, grey-white crust that was visibly raised above the skin, measuring almost 3 cm in

diameter. Typically, these lesions were found on the neck and head, particularly around the eyes and face. However, in animals with severe disease, these lesions may be observed throughout the entire body (Apaydin and Atalay 2007; Radostits *et al.* 2007)^[1, 8].

2.2 Sampling and Lab Examination

From September 2022 to April 2023, the LFC at Apollo College of Veterinary Medicine in Agra Road Jaipur examined 20 cattle calves of different breeds like Gir, H.F cross breed and Mewati with diverse skin lesions. The breed, age, and clinical appearance of the lesions were recorded on the spot. All animals presented with suspected skin disease, characterized by round lesions with embossed edges occurring in any part of the body. We recorded crucial information such as breed, age, and clinical appearance of the lesions to better understand the nature of the disease.

Microscopic examination in dermatophyte infection diagnosis has been used through different diagnostic techniques. A small portion of each skin scraping was subjected to digestion in 20% potassium hydroxide (KOH) through heating, followed by direct microscopy in lactophenol cotton blue (LPCB) stain, in accordance with standard protocol. Additionally, a wet mount of each skin sample was prepared and examined for the presence of macroconidia and mycotic hyphae using standard techniques. Concurrently, suspected samples were incubated at 27 °C and 37 °C for three to four weeks on Sabouraud's dextrose agar, supplemented with chloramphenicol and cycloheximide, and identified based on the morphological characteristics of the thallus, hyphae, macroconidia, and microconidia (Quinn *et al.* 1994)^[7].

Colony formation typically manifests within 7-14 days, making it a crucial indicator of dermatophytosis. To effectively combat this condition, it is imperative to identify the source through fungal cultures and implement targeted preventive measures. In cases where diagnosis is uncertain or standard therapy proves ineffective, culture may also be necessary. *T. verrucosum*, for instance, is identifiable by its slow-growing, non-pigmented, cottony white colonies with a heaped-up, button-like appearance and folded areas (Dalis *et al.* 2014; Eman-abdeen 2018)^[2, 4].

2.3 Treatment and Control

Dermatophytosis is a public health concern and treatment is recommended to shorten the course of infection and minimize the chances of transmission. Treatment includes three key aspects:

- Antifungal treatment for the animal
- Reasonable confinement to limit contagion
- Cleaning of the environment to remove infective spore

There are a variety of antifungal agents available for treating fungal infections in animals, including Sulphur preparations, Lime Sulphur, Enilconazole, Griesofulvin, Ketoconazole, Sodium Tolnaftate, and even fluorides found in toothpaste. However, for larger animals, the cost of prolonged and sophisticated treatment lasting 15-30 days can be a challenge for owners. Our mission is to provide cost-effective and efficient treatment options for animals in need. To achieve this goal, we have utilized a 2% liquid Povidone iodine and Whitfield's ointment for the treatment of all animals. This treatment is administered twice a day for 15 consecutive days. Prior to the application of these medications, the lesions are

thoroughly cleaned with normal saline. Both medications are topically applied to the affected areas.

3. Results and Discussion

Figure 1, 3, and 5 exhibit characteristic lesions such as circular, circumscribed alopecia, and grey-white crust on the neck, ears, and muzzle. These images were captured prior to treatment. Conversely, Figure 2, 4, and 6 do not display any such lesions as they were taken after treatment. It is evident that the treatment has been effective in eliminating the aforementioned lesions. Iodine is effective against both Gram-positive and Gram-negative bacteria, fungi, and protozoa. It quickly infiltrates microorganisms and oxidizes essential proteins, ultimately destroying the cell. On the other hand, Whitfield's ointment, a century-old remedy for dermatophyte, reduces cohesion between keratinocytes, exfoliating the stratum corneum and removing dead, infected skin. Their approach to treating fungal infections in animals is cost-effective and highly effective, reflecting their commitment to providing the best possible care for affected animals.

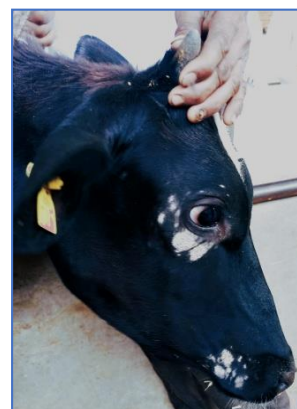

Fig 1: Exhibit characteristic lesions such as circular, circumscribed alopecia, and grey-white crust on the neck, ears, and muzzle




Fig 2: Images were captured prior to treatment



Fig 3: Exhibit characteristic lesions such as circular, circumscribed

alopecia, and grey-white crust on the neck, ears, and muzzle




Fig 4: images were captured prior to treatment

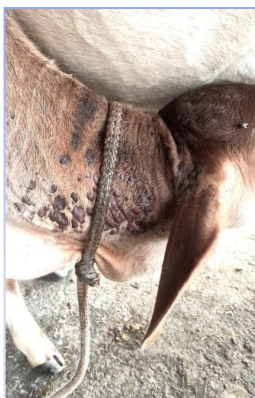

Fig 5: exhibit characteristic lesions such as circular, circumscribed alopecia, and grey-white crust on the neck, ears, and muzzle

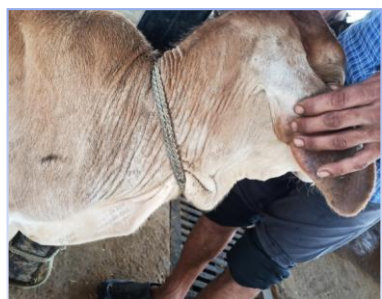

Fig 6: images were captured prior to treatment

Conclusion

Bovine dermatophytosis, also known as ringworm, is caused by *T. verrucosum* and can spread from animals to humans through direct contact. It's important to take preventative measures to avoid the spread of this disease and seek medical attention if symptoms arise. Our cost-effective treatment options for fungal infections in animals reflect our commitment to providing the best possible care for animals in need.

5. References

1. Apaydin N, Atalay Ö. Efficacy of ethylenediamine dihydriodide for the treatment of ringworm in young cattle. *The Veterinary Record*. 2007;160:408-410.
2. Dalis JS, *et al.* An outbreak of ringworm caused by *Trichophyton verrucosum* in a group of calves in Vom, Nigeria. *African Journal of Microbiology Research*, 2014;8(8):783-787.
3. Dalis JS, Kazeem HM, Kwaga JKP, Kwanashie CN,

Yakubu B, Owolodun OA, *et al.* Molecular characterization of dermatophytes isolated from cattle in Plateau State, Nigeria. *Veterinary Microbiology*. 2018;219:212-218.

4. Eman-abdeen, Walid Moosa S. Overview on bovine dermatophytosis. *The International Journal of Veterinary Science and animal husbandry*. 2018;3(2):16-19.
5. Gudding R, Lund A. Immunoprophylaxis of bovine dermatophytosis. *The Canadian Veterinary Journal*. 1995;36(5):302-306
6. Markey B, *et al.* *Clinical veterinary microbiology* (e-book), 2nd Ed., Mosby Elsevier, Health Sciences, New York; c2013.
7. Quinn PJ, Carter ME, Markey B, Carter GR. *Clinical Vet Microbiology*. Wolf publishing, 1994, 381-390, England.
8. Radostits OM, *et al.* *Dermatomycoses in Diseases associated with algae and fungi, A textbook of the diseases of cattle, horses, sheep, pigs and goats Veterinary medicine*, 10th Ed., Saunders Elsevier, New York; c2007.